

THE 'WHY,' 'WHAT' AND 'HOW' OF FITTING THE CROSSOVER BITLESS BRIDLE

W. Robert Cook FRCVS, PhD¹

"There is nothing more difficult to take in hand, more perilous to conduct, or more uncertain in its success, than to take the lead in the introduction of a new order of things."

- Niccolo Machiavelli (1469-1527)

INTRODUCTION

The correct fitting of the new crossover design of bitless bridle is quite simple. There are only two things to remember; the noseband should be fitted low and snug. Numerical guidelines are provided in the manual that comes with the bridle and if these are followed there should be no problem (see also Fig 1).

However, whenever there is only one way to do something correctly, there are always many ways to do it incorrectly. As this applies to the crossover bitless bridle, some understanding of the anatomy of the horse's head, will avoid disappointment. When fitted correctly, it is the experience of hundreds of users that the new bridle provides the safest and most effective method of communication that has yet been devised (see the Users' Comments online at www.bitlessbridle.com). It is also the only bridle that is painless, compatible with the physiology of the exercising horse, and universally suited to all disciplines (notwithstanding the current regulations of the Federation Equestre Internationale and other organizations that do not yet permit its use for competition purposes). But when fitted incorrectly, some of its effectiveness may be lost and riders then criticize the method unfairly.

After 6000 years of bitted bridles, a painless and comprehensive method of bitless communication has finally been developed. The new method represents a landmark advance in equine welfare and the art of equitation. Care must now be taken that the benefits of this advance are not lost as a result of reports from people who have fitted the bridle incorrectly.

Just as the most important features to remember are that the noseband should be fitted low and snug, the most common mistakes in fitting arise from a failure to observe these two criteria. Human nature being what it is, this can come about

¹ Professor of Surgery Emeritus, Tufts University School of Veterinary Medicine,
200 Westborough Road, North Grafton, MA 01536 USA
Chairman, The Bitless Bridle Inc.
Tel: (410) 778 9005. E-mail: drcook@bitlessbridle.com. Online at www.bitlessbridle.com

in at least three ways. Simple failure to read the manual is the first way. We have all experienced a reluctance to read the instructions that accompany a new device. A second way arises from the force of tradition. For generations we have been taught that a plain cavesson noseband should be placed two fingers below the projecting cheek bones (facial crest). So recommendations that defy this tradition must surely be wrong. Thirdly, there is a belief among riders that a low noseband obstructs breathing. This belief arises, however, from a misunderstanding of anatomy. It is falsely assumed that a low noseband is necessarily lying on cartilage rather than bone, and that as pressure on cartilage would tend to suffocate a horse this should be avoided at all costs. The last part of this argument is correct but not the first.

This article has three objectives. First, to explain where bone stops and cartilage begins (see legend # 3 on Fig. 2). Secondly, to show that the crossover bitless bridle is uniquely compatible with the physiology of the horse at exercise. Thirdly, to provide an introduction to some of the form and function reasons (anatomical and physiological reasons) why the bit method of communication is contraindicated, counterproductive and cruel (Cook 1999a, 1999b, 2000, 2002, 2003a & b, and Cook & Strasser 2003). The objectives can be most conveniently achieved by a study of Figures 1 to 3.



Figure 1: Showing the correct fitting for the crossover bitless bridle on an adult Tennessee Walking Horse, with the noseband low and snug.

CORRECT FITTING FOR THE CROSSOVER BITLESS BRIDLE

The noseband is placed much lower on the horse's head than the plain cavesson of a bitted bridle. In an average-sized horse the bottom edge of the noseband should lie between 3.8 and 5.0 cm (one-and-a-half to two inches, or about two fingers) above the corner of the mouth (Fig. 1). At this height there is no danger of the noseband obstructing the airway. If the noseband is placed higher than recommended, the advantage of leverage is forfeited and the rider may experience some loss of control. With a compliant horse this will not be of any consequence but with an eager horse the rider will have to work too hard and may finish the ride with sore shoulders.

Once the height of the noseband is correctly adjusted, the chinstrap is buckled-up so that it is snug but not tight. One should be able to get just one flat forefinger between the chinstrap and the bottom edge of the jawbone. By 'flat' it is meant that the fingernail should touch the bone and the pad of the finger should touch the chinstrap. Note that this check takes place under the bone and not under the soft tissues at the center of the jaw. Care must be taken that the crossover straps are not trapped under the chinstrap. Failure to buckle-up the chinstrap sufficiently results in the noseband riding up the head too far at each application of rein pressure. This can result in a cosmetic loss of hair but it can also result in some loss of control. A snug noseband can cause no discomfort as long as the horse's cheek teeth have no sharp edges. A noseband that is tight rather than snug will cause the same sort of intense pain that we experience if goggles or spectacles are fitted incorrectly. In addition, the rider cannot provide any 'release' for the horse.

As with all bridles, one should check that the browband fits comfortably around the base of the ears. A browband that is too tight may cause headshaking.

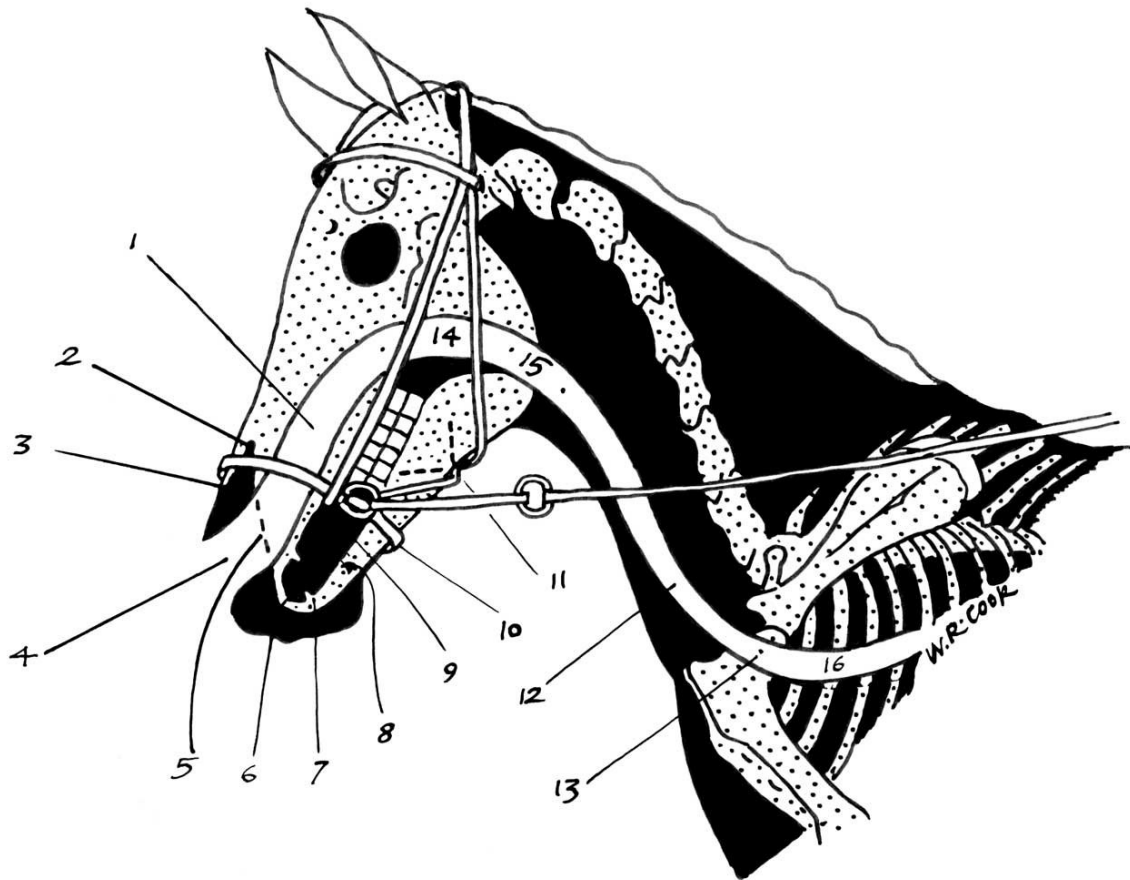


Figure 2. A diagrammatic version of Figure 1, showing how the correctly fitted noseband relates to the anatomy of the region.
Key: white = airway; black = soft tissue (including cartilage); dotted areas = bone. The numbered paragraphs in the text below provide the key to the numbered legends in the diagram.

FORM AND FUNCTION

Figure 2 shows the nostril dilated as for exercise. But remember that the diagram is based on the photograph of a horse at rest, so the position of the head is not really appropriate for fast exercise as the airway is too bent. If the crossover bitless bridle (BB) is fitted correctly, it should be possible to palpate the premaxillary notch lying just above the top edge of the noseband (see legend #2). This is a landmark that can be used to check the fit of the bridle on horses of all sizes from draft to miniature. Obviously, the recommendation with regard to the distance of the noseband above the corner of the mouth will vary slightly with the size of the horse, but the premaxillary notch provides a constant.

1. Nasal cavity. The two scrolls of delicate bone in the nasal cavity (the turbinate bones) create three longitudinal channels (upper, middle, and lower). The upper and middle channels function as dust filters and assist the sense of smell in the resting horse. Much the largest channel and the one that provides a direct pathway from nostril to throat is the lower channel. This is the main airway for the horse both at rest and at exercise. Accordingly, this is the one depicted in the diagram. Notice how this lower channel, at the level of the noseband, is shielded by a wall of bone (the incisive bone and the maxilla). Even if the noseband was tight, rather than snug, it could not interfere with the airway.
2. Premaxillary notch. The ability to palpate the top of this notch provides the final check that the noseband is at the correct height. In the resting horse, the nostril is relaxed and the false nostril (nasal diverticulum) occupies the large black triangle above and below the noseband. In the resting horse, the false nostrils are two dead-end pouches that lie on the outside of each nostril (see Fig. 3). In the exercising horse, however, the nostrils are dilated. This has the effect of obliterating the false nostrils. The space that they used to occupy now increases the size of the nostrils. Flaring of the nostril provides a funnel-like entrance to the airway that, in the running horse, facilitates the rapid and smooth flow of huge volumes of air. The presence of the noseband, bridging the gap between two bones at the level of the notch, cannot interfere with the passage of air. First, the noseband is supported by bone on each boundary of the notch and, secondly, the main airflow does not involve this region anyway.

[Incidentally, these anatomical and physiological facts are relevant to the debate over whether nasal strips enlarge the airway in racehorses. The facts are such that the use of nasal strips cannot possibly be of any benefit. First, unless a horse has a facial paralysis (extremely rare), its nostrils do not collapse during a race. Secondly, even if the nostrils did collapse, nasal strips would not be of any help because they have no influence over the size of the airway. The situation in man is different but then our anatomy is different. We do not have the false nostrils of the horse. If trainers wish to improve the airway of their horses they can do this by removing the bit (see below)]

3. Peak of the nasal bone. Note that this is bone and not cartilage. It is not liable to be bent or compressed as the result of the relatively trivial pressure exerted by the noseband of the crossover BB. Cartilage that extends forward from the peak of the nasal bone provides the support for two comma-shaped cartilages (the alar cartilages) that form the wings of the nostril. All these cartilaginous structures are represented by the black area between the tip of the nasal bone and the nostril.

4. Nostril (anterior nares). Note the funnel shape of this entrance to the airway during fast exercise and remember that there are two of them. The nasal airway is a dual carriageway, separated only by a sheet of cartilage, the nasal septum (see also Fig 3). As implied by the anatomical name for the nostrils there are also posterior nares. In Fig. 2 the posterior nares are sited at the black dot that separates the nasal cavity (#1) from the throat (#14). Their existence is worth noting because the posterior nares are a potential site of serious airway obstruction. Any elevation of the soft palate (the floor of the throat) constricts the posterior nares. The soft palate is attached to the hard palate (the roof of the mouth and floor of the nasal cavity) and hinges at this critical point where the nasal cavity joins the throat. In the author's opinion, the most common cause of elevation of the soft palate is the presence of a bit in the horse's mouth (see paragraph # 14 and Cook 2002).
5. Front edge of the premaxilla or incisive bone (the bone that houses the incisor teeth or nippers). Note that the noseband is firmly supported on each side by this bone that forms the outside wall of the nasal cavity.
6. Point of contact between upper and lower lip. In this representation of a relatively normal airway at exercise, the mouth is closed, the lips are sealed, and no air is permitted to enter the oral cavity. An open mouth at exercise is not normal (physiological) as air gets into the back of the mouth and is one cause of elevation or dorsal displacement of the soft palate (DDSP). DDSP constricts the airway at the throat (see legend #14). The word 'relatively' is used because if this particular horse were performing maximally its head and neck would have to be extended to straighten out the airway. In the position depicted, the airway is obstructed by virtue of poll flexion and high head carriage. This produces two sharp bends in the airway, one at the throat and the other at the entrance to the chest. Unfortunately, with the bit method of communication it is only too easy for the rider to cause both poll flexion and a high head carriage (false collection).
7. Canine tooth in the lower jaw. The root of this tooth occupies most of the space in the jawbone, as far back as the mental foramen (#8). The tooth's presence in the male horse probably accounts for the higher incidence in male horses that are also bitten of facial neuralgia (the headshaking syndrome). Mares do not generally have canine teeth and when they do the teeth are much smaller (vestigial).
8. Mental foramen. This is the point of emergence of the mandibular nerve, which supplies sensation to the gums (including the bars of the mouth), incisor teeth, lower lip and chin. In a bitted horse, the bit lies on the bars immediately above this highly sensitive region. Pressure from the bit on the gum at the bars of the mouth causes periostitis, which commonly

- results in bone spur formation (Cook 2002). Gum is a specialized form of periosteum (skin of the bone). Superficial inflammation of the gum is called gingivitis but deep-seated inflammation is called periostitis (bone spur formation). Bone spurs, in turn, are a cause of headshaking.
9. Oral cavity. Actually, the legend points to the bars of the mouth but it is the black region above the bars that represents the front half of the oral cavity (mouth). The back half of the mouth lies between the first five cheek teeth. At the level of the fifth cheek tooth, the oral cavity continues as the oral part of the throat (in the diagram, the black region behind the last cheek teeth). Compared with man, the horse has an unusually long and narrow oral cavity and throat. But the word 'cavity' as applied to the oral cavity is somewhat misleading because, when exercising rather than eating, both the oral cavity and the oral part of the throat are potential cavities only. In a horse at liberty (or in a horse ridden in the crossover BB) both the oral cavity and the oral part of the throat are entirely occupied by the tongue. There is no 'cavity' as such, as all air is excluded. The oral cavity is filled with the tip and body of the tongue, and the oral part of the throat is filled with the root of the tongue.
 10. Chinstrap. This is a continuation of the noseband. In the diagram it might appear to be attached to the 'O' ring, but the 'O' ring is itself attached to the noseband. The scale of the diagram is not large enough to show this clearly. Notice that the chinstrap lies outside the cheek at the level of the first cheek tooth in the upper jaw. A snug chinstrap could press the cheek against a sharp enamel edge on this tooth, so any such defects should be corrected when using the crossover BB.²
 11. Crossover straps, each continuing in the direction indicated by the broken line. Notice that the gentle pressure applied by the straps lies away from the teeth and over relatively insensitive tissues such as the side of the jaw and the muscle of the cheek. Pressure elsewhere is also well-distributed and applied to relatively insensitive tissue. Compare this with the focused pressure of a bit on the highly sensitive tissues of the mouth.
 12. Windpipe (trachea). A high head carriage causes the windpipe to be compressed at the entrance to the chest. Any obstruction of the nasal cavity, throat or voice box will tend to cause a collapse of the windpipe and further obstruction (Cook & Strasser 2003)
 13. Entrance to chest at the level of the first rib. This is the dividing point between the upper and lower airways (see also Fig 3).

² 'The Bitless Bridle.' Manufacturer's address: The Bitless Bridle Inc., 2020 South Queen Street. York, PA 17403-4829. Telephone toll free 866 235 0938 and online at www.bitlessbridle.com

14. Respiratory part of the throat (nasopharynx). The throat has an upper (respiratory) and a lower (digestive) level. The two regions are separated by the long soft palate of the horse, which forms the floor of the respiratory part of the throat (the nasopharynx) and the roof of the oral part of the pharynx (the oropharynx). When a horse is eating, the oral part of the throat takes precedence over the respiratory part and enlarges at its expense. Conversely, when a horse is galloping, the respiratory part of the throat enlarges at the expense of the oral part. But note that this is only the situation in the horse at liberty or in a horse that is galloping in a crossover BB. This is not the situation when a horse is galloped in a bitted bridle (Cook and Strasser 2003). As the horse depicted in this diagram is exercising, the respiratory part of the throat is open and the digestive part of the throat is closed. During deep breathing as for exercise, the oral part of the throat (oropharynx) is, in normality, a potential space only as it is entirely occupied by the root of the tongue. Unfortunately, because a bit breaks the normal seal of the lips at exercise, air often creeps back into the oral part of the throat and causes the soft palate to billow upwards. As already mentioned, this is one cause of DDSP. A second cause is retraction of the tongue behind the bit, as this results in elevation of the soft palate on the bunched-up root of tongue. These and other causes of DDSP are described more fully in previous publications (see bibliography).
15. Voice box (larynx). The common name for this structure incorrectly suggests that voice production is its most important function. In fact, the larynx is a valve in the floor of the throat, at its tail end. The most important function of the larynx is to open to facilitate the flow of air during exercise, and to close to prevent food or water from inundating the lungs during swallowing. Unfortunately, the presence of a bit in the oral cavity of a horse at exercise sends inappropriate messages to the brain and the horse is physiologically confused as to whether it should be breathing or swallowing. This confusion explains why many a horse chokes at exercise.
16. Lower airway. This section of the airway comprises the windpipe within the chest, the two bronchi and the small airways of the lung (see also Fig 3). Like every other mammal, a horse inhales by expanding the chest and flattening the diaphragm. This creates a negative atmospheric pressure in the air sacs of the lungs and air rushes in to fill the vacuum. The mechanism works well as long the upper airway is not obstructed. Unfortunately, the bit method of communication is, for a variety of different reasons, a frequent source of upper airway obstruction (Cook & Strasser 2003). The abnormally intense negative pressure that results from any upper airway obstruction easily damages the delicate air sacs of the lung and the small airways. The damage is inflicted twice a second in a cantering horse and more frequently in a galloping horse. The end result of this barometric bruising is bronchiolitis, pulmonary congestion, and

edema of the lung ('waterlogging'). It is edema of the lung that is the basic pathology behind what is commonly referred to as 'bleeding' (so-called exercise-induced pulmonary hemorrhage or EIPH). The author believes that a more accurate name for 'bleeding' is asphyxia-induced pulmonary edema or AIPE (Cook 1999b). Another common cause of upper airway obstruction is hereditary recurrent laryngeal neuropathy (laryngeal hemiplegia). As this is a disease that is impossible to treat and difficult to prevent, it is all the more important to eliminate those causes of upper airway obstruction that are avoidable. In the author's opinion, removal of the bit would do much to reduce the prevalence of pulmonary disease in the horse.

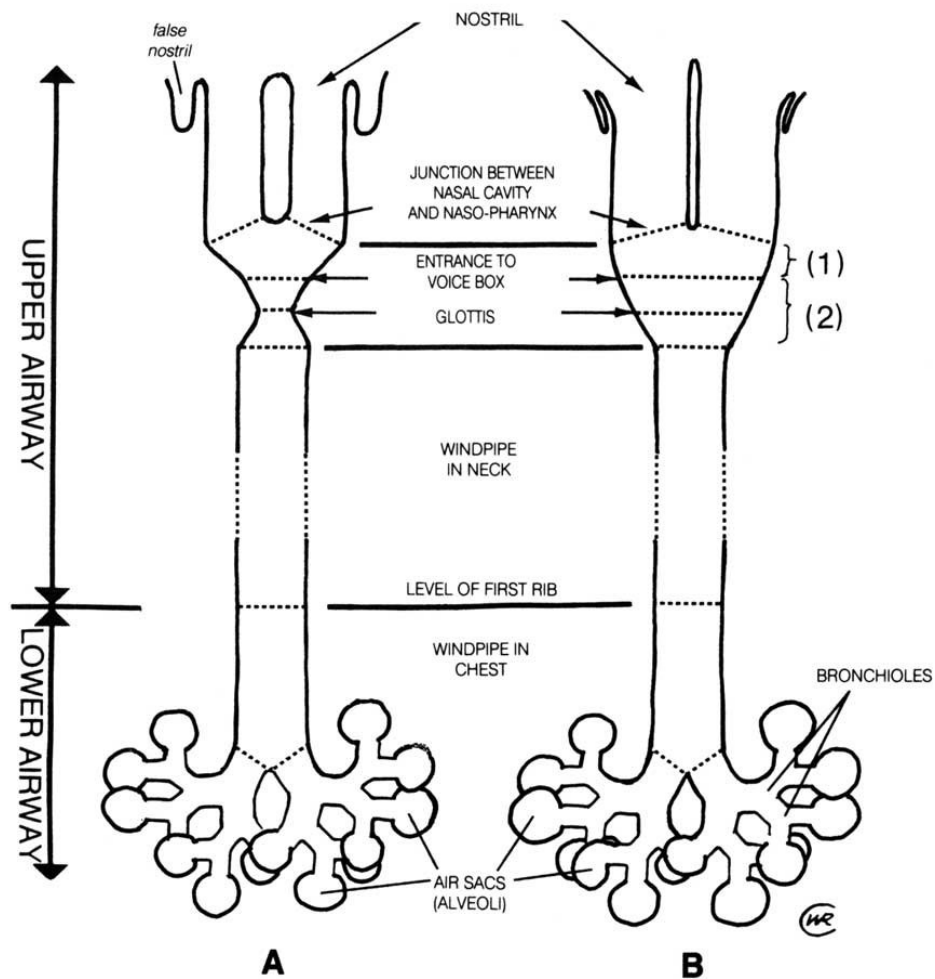


Fig. 3. A bird's eye view of the respiratory tract of a horse at rest and at exercise. Key: 1 = throat (nasopharynx); 2 = voice box (larynx)

Figure 3 illustrates many of the ways in which the healthy airway is enlarged to facilitate the huge increase in airflow that occurs at exercise. At rest (A), a horse may breathe at the rate of 8/minute but at the gallop (B) the rate may

be as high as 150/minute. Of particular relevance to this article, is the elimination of the false nostril in the exercising horse, as illustrated (Fig. 3). The nasal airway is further enlarged at exercise by a constriction of blood vessels in the nasal mucous membrane. But the throat and voice box also expand considerably in the healthy horse at liberty. For reasons already given, the expansion of the throat and voice box in the bitted horse may not take place. On the contrary, their size may be reduced.

CONCLUSION

The above explanations of form and function are all relevant to a comparison of the merits of the crossover BB and the bit. However, one important aspect of physiology has not been stressed ... bit-induced pain. This is something that cannot be illustrated. It requires a study of behavior to demonstrate the fact that the most important (and dangerous) effect of the bit is to frighten the horse. For further information about bit-induced pain see Cook (2003b).

BIBLIOGRAPHY³

1. Cook, W.R.: Pathophysiology of Bit Control in the Horse. *Journal Equine Veterinary Science* 19: 196-204, 1999a
2. Cook, W.R.: The ear, the nose, and the lie in the throat. In *"Guardians of the Horse: Past, Present and Future."* Ed: Rosedale, P.D., Greet, T.R.C., Harris, P.A., Green, R.E., and Hall, S.. British Equine Veterinary Association and Romney Publications, 1999b, pp 175-182.
3. Cook, W.R.: A solution to respiratory and other problems caused by the bit. *Pferdeheilkunde*, 16, 333-351, 2000
4. Cook, W.R.: Bit-induced asphyxia in the horse: Elevation and dorsal displacement of the soft palate at exercise. *Journal of Equine Veterinary Science*, 22, 7-14, 2002
5. Cook, W.R.: Bit-Induced Pain: a cause of fear, flight, fight and facial neuralgia in the horse. *Pferdeheilkunde*, 19, 1-8, 2003a
6. Cook, W.R.: Fear of the Bit: A welfare problem for horse and rider. Parts I – III. Online at www.bitlessbridle.com 2003b
7. Cook, W.R. and Strasser H. *"Metal in the Mouth: The abusive effects of bitted bridles."* Sabine Kells. Qualicum Beach, British Columbia, Canada. 2003

³ Many of these articles are available online at www.bitlessbridle.com